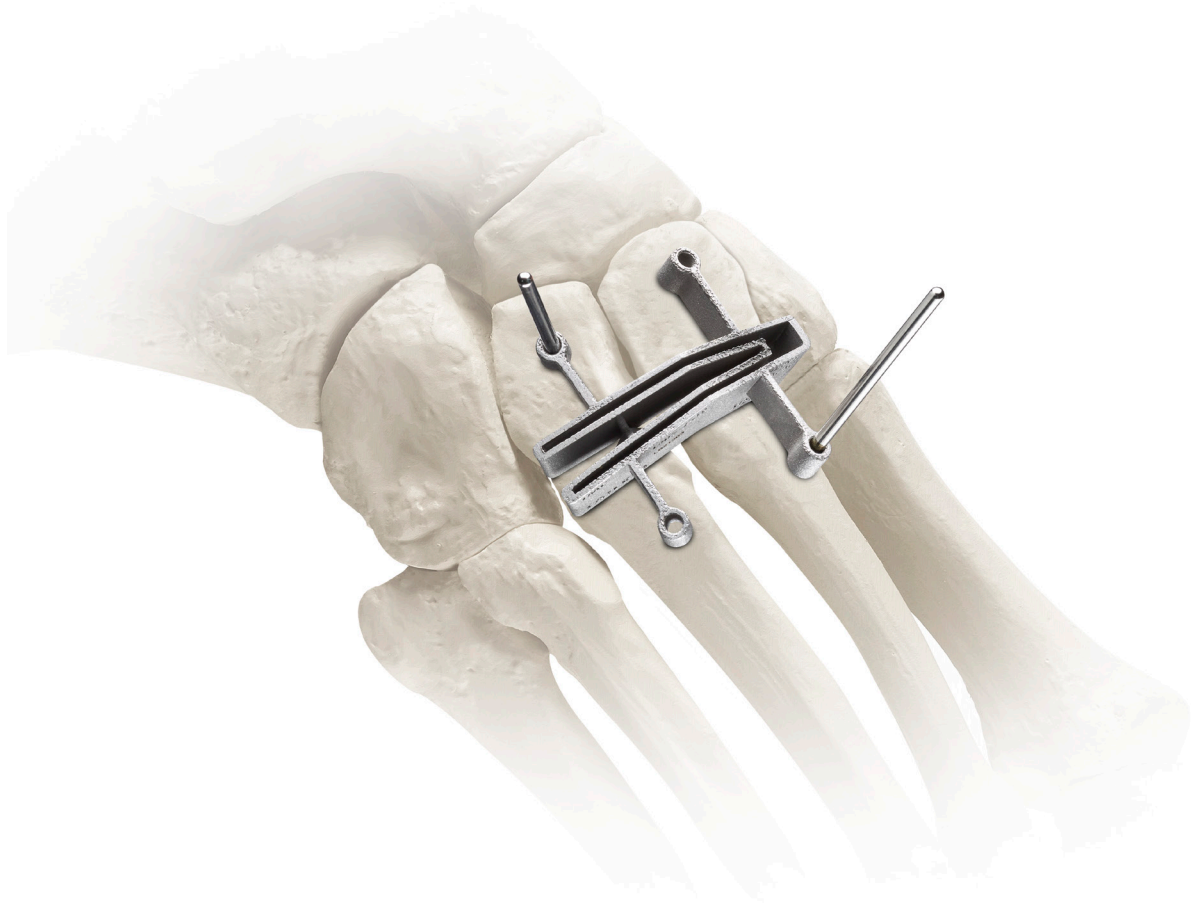

Adductoplasty™

Midfoot Correction System

Key Steps and Fluoro Checks



Instrumented Approach for Corrective
2nd & 3rd TMT Joint Arthrodesis

TREACE[®]
Medical Concepts, Inc.
The Leader in Hallux Valgus Surgery™

Adductoplasty™

Midfoot Correction System

Bringing together **Lapiplasty® Lesser TMT Fixation** and **precision Adductoplasty™ instrumentation** for the first, comprehensive system designed for reproducible realignment, stabilization, and fusion of the midfoot.

Plane.

The **Adductoplasty™ Planer** allows for congruent planing of the 2nd & 3rd TMT joint surfaces (for insertion of the **Adductoplasty™ Lesser TMT Cut Guide**).

Cut.

The **Adductoplasty™ Lesser TMT Cut Guide** is designed to deliver precise, continuous angular cuts of the 2nd & 3rd TMT joints.

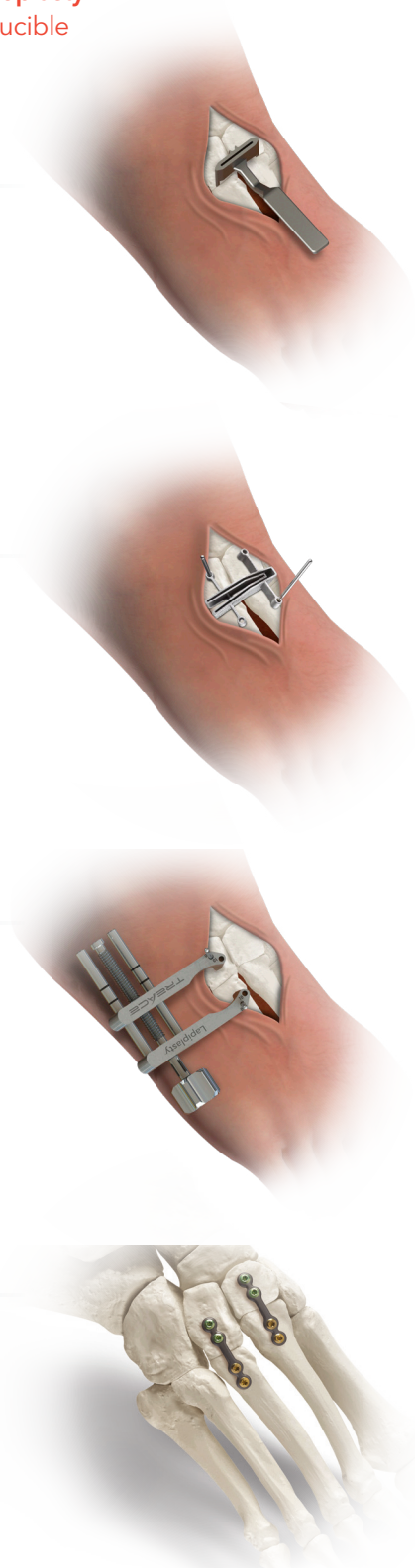
Compress.

The **Lapiplasty® Compressor** delivers controlled apposition and compression¹ of the corrective arthrodesis.

Fixate.

The low-profile titanium plates of the **Lapiplasty® Lesser TMT Fixation System** are designed to provide locking fixation for corrective arthrodesis of the lesser TMT joints.

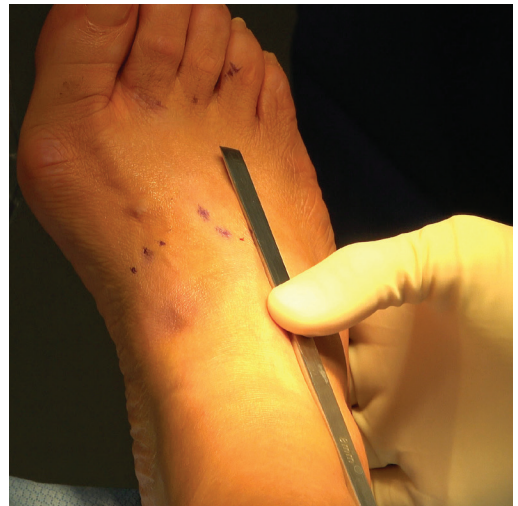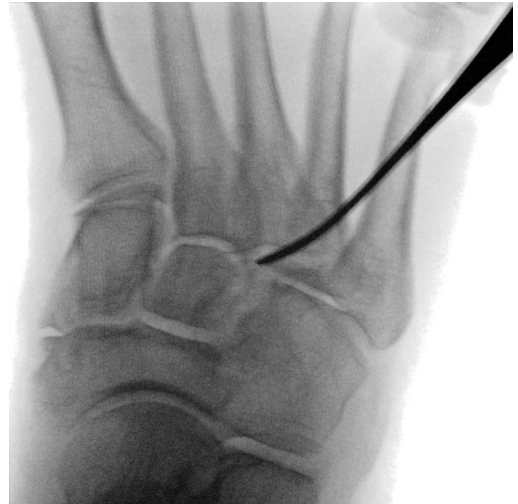1. Data on file.



Surgical Approach

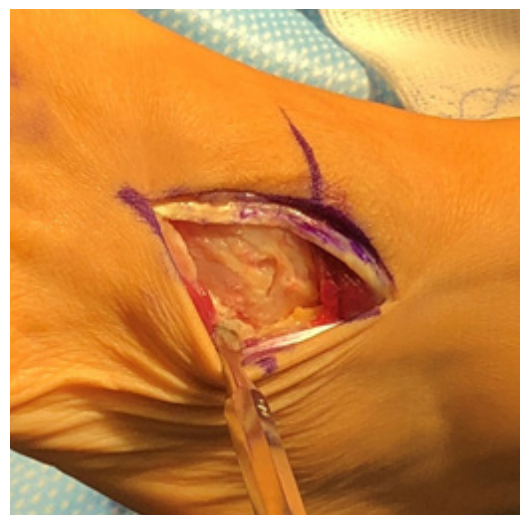Begin the procedure by locating the 2nd and 3rd tarsometatarsal (TMT) joints under fluoroscopy with a lateral oblique view. Mark a longitudinal incision extending 6-8cm in length proximal to distal, centered over the 3rd TMT joint.

Note: If also performing a 1st TMT arthrodesis procedure, it is important to ensure an adequate skin bridge (approximately 4cm or greater) between the two incisions.



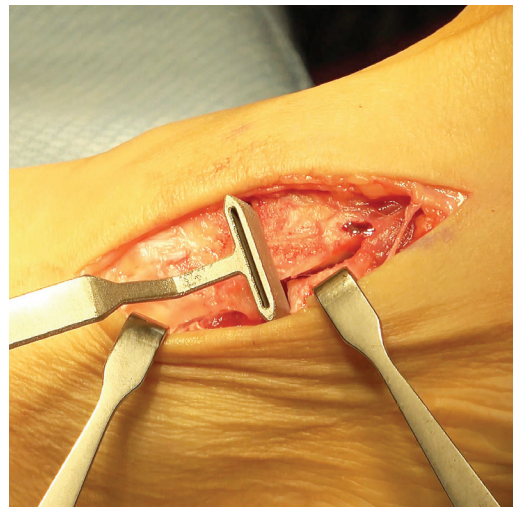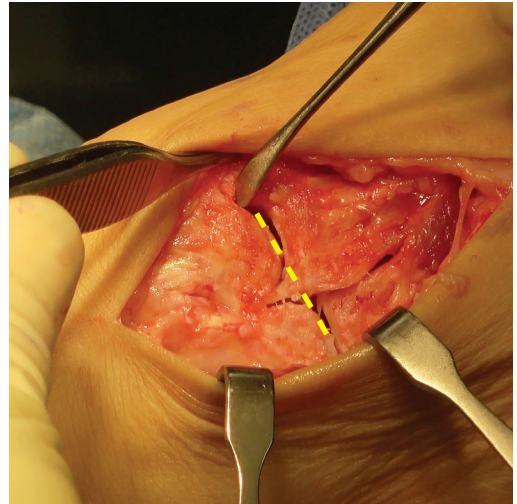
Joint Exposure and Dissection

Carefully dissect through the skin, subcutaneous tissue, and retinaculum taking care to leave the ligamentous attachments between the 2nd and 3rd metatarsals intact. Retract between the extensor digitorum longus (EDL) and extensor digitorum brevis (EDB) muscle. Locate and expose the 2nd and 3rd TMT joints. Completely release the interval between the 3rd and 4th metatarsal base with an osteotome.



Plane the 2nd & 3rd TMT Joint

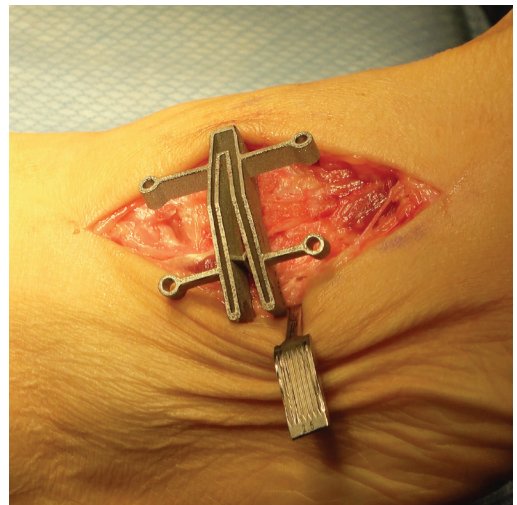Insert the prongs of the **Adductoplasty™ Planer** into the corresponding 2nd and 3rd TMT joints, ensuring the cut slot trajectory is coincident with the sagittal plane. Using a sagittal saw, advance the saw blade through the slot of the **Planer** to plane the offset between the 2nd & 3rd TMT joints. This creates continuous, congruent joint surfaces for insertion of the **Adductoplasty™ Lesser TMT Cut guide**.



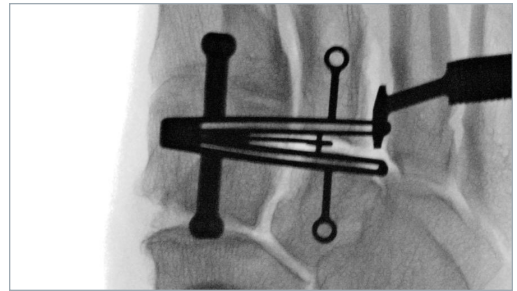
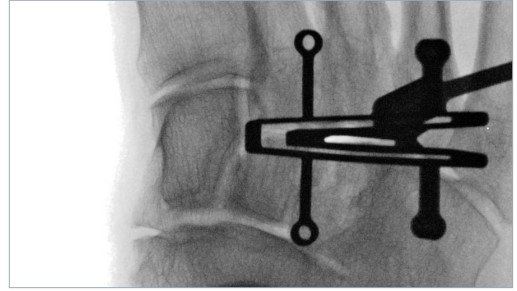
Cut Guide Application

Insert the keel of the **Lesser TMT Cut Guide** into the planed 2nd and 3rd TMT joints, ensuring the cut slots extend to the medial aspect of the 2nd TMT joint. Assess the **Lesser TMT Cut Guide** position (i.e. sagittal and transverse plane alignment) clinically and with oblique fluoro images down the 2nd and 3rd TMT cut slots.

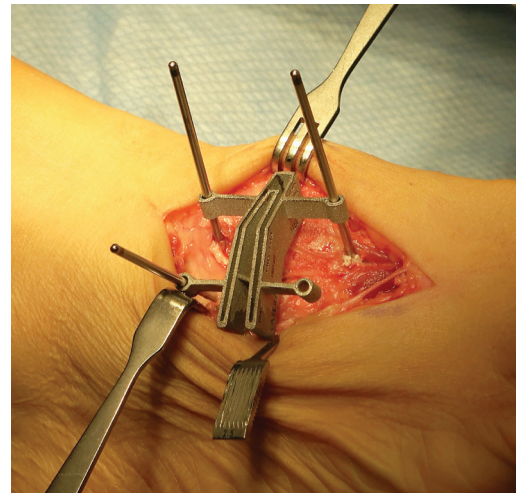
Note: The Fulcrum can be inserted between the 3rd & 4th metatarsal bases to help serve as a retractor and protect the 4th metatarsal when making cuts.



Note: When obtaining the proper “down the joint” fluoro view, the **Lesser TMT Cut Guide** fixation holes should become “perfect circles.”



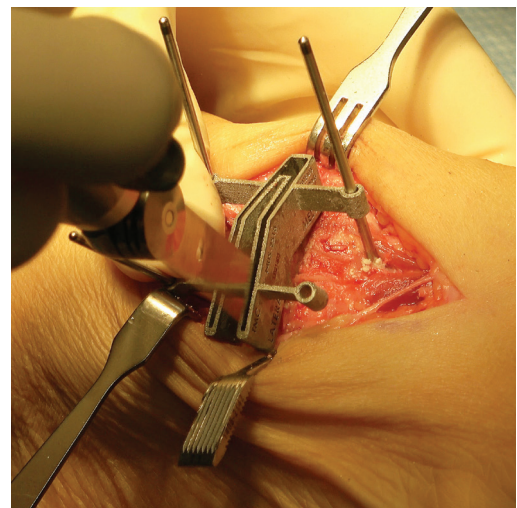
To secure the **Lesser TMT Cut Guide**, insert at least two 2mm half-pins into the cuneiform and/or metatarsal fixation holes.



Metatarsal and Cuneiform Bone Cuts

Utilize the sagittal saw to make bone cuts across the 2nd and 3rd TMT joints in both the metatarsal and cuneiform slots of the **Lesser TMT Cut Guide**, ensuring the saw is kept perpendicular to each cut slot.

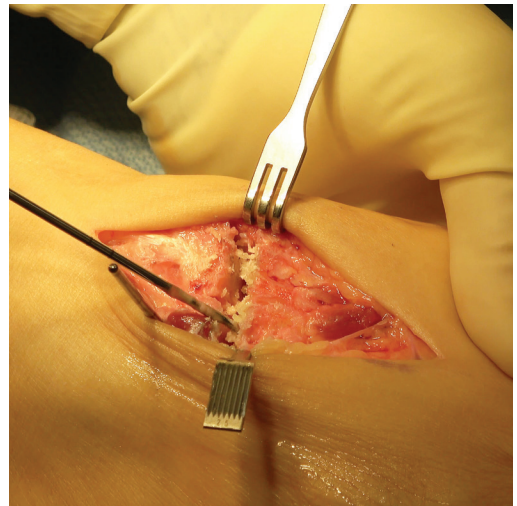
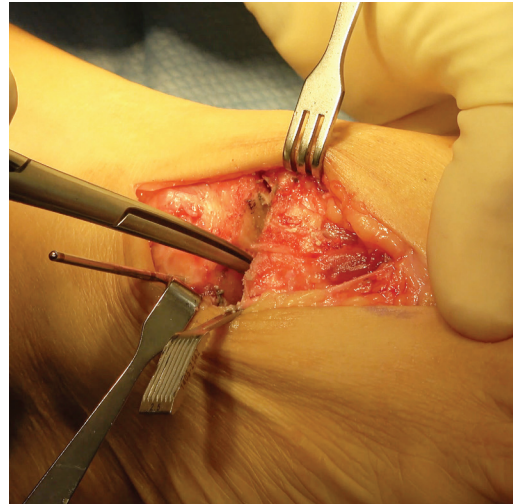
Note: The **Lesser TMT Cut Guide** is angled in the frontal plane to accommodate the transverse arch of the foot.



Prepare and Fenestrate TMT Surfaces

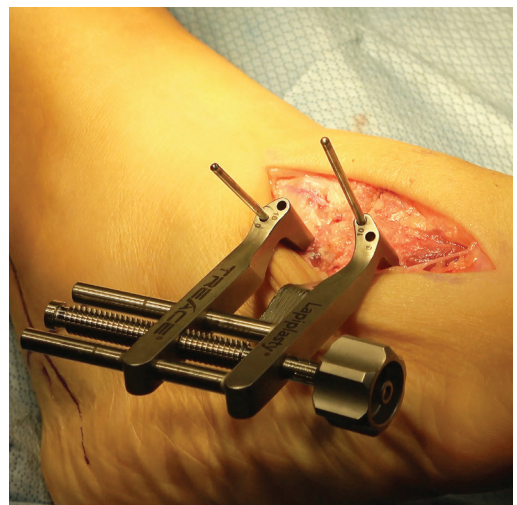
Leaving the half-pin in the 3rd cuneiform, remove the other 2mm half-pins from the **Lesser TMT Cut Guide** and slide the cut guide off. Utilize a pituitary or a long, straight rongeur to remove the bone slices and/or any remaining plantar fragments of bone. Inspect the joint surfaces to confirm that all articular cartilage has been removed, using a curette as necessary to remove residual cartilage.

Aggressively fenestrate the 2nd and 3rd TMT subchondral joint surfaces with a 2mm fluted drill bit.

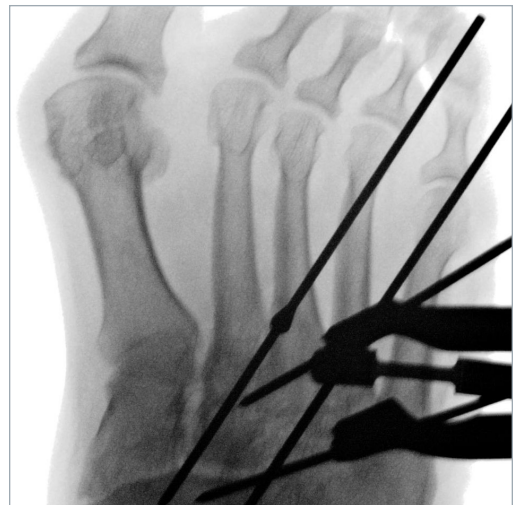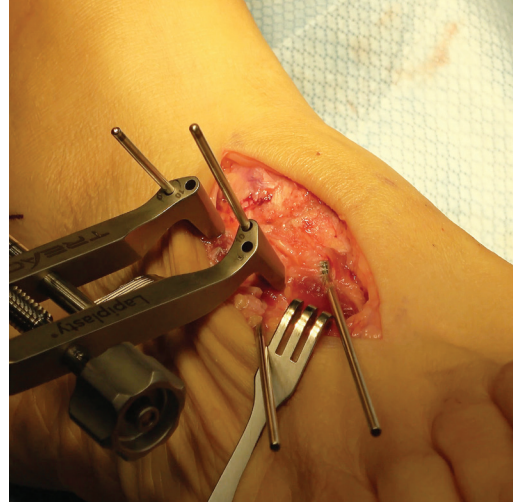


TMT Compression & Provisional Fixation

Slide the **Lapiplasty® Compressor** over the half-pin in the 3rd cuneiform. Manually compress the arthrodesis site, then insert a half-pin through the **Compressor** into the 3rd metatarsal. Tighten the **Compressor** to appose the joint surfaces utilizing "two-finger tightness" and confirm uniform apposition of the 2nd and 3rd TMT joint surfaces clinically and on fluoroscopy.

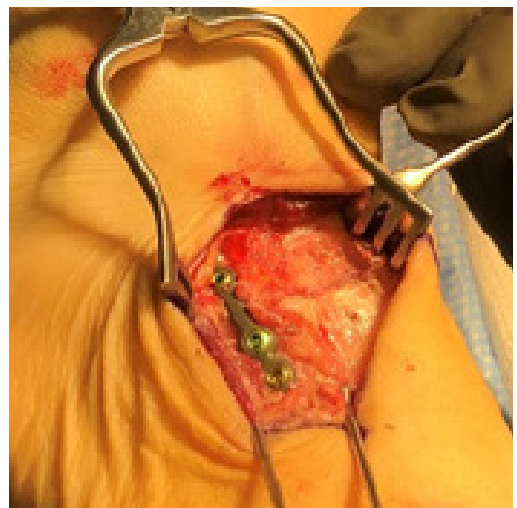


For provisional fixation, insert a **2mm Threaded Olive Wire** from the lateral cortex of the 3rd metatarsal into the 3rd cuneiform. Insert a 2nd **Threaded Olive Wire** across the 2nd TMT joint from the lateral cortex of the 2nd metatarsal and confirm the reduction on fluoroscopy. Remove the 2mm half-pins from the **Compressor** to remove the **Compressor**.

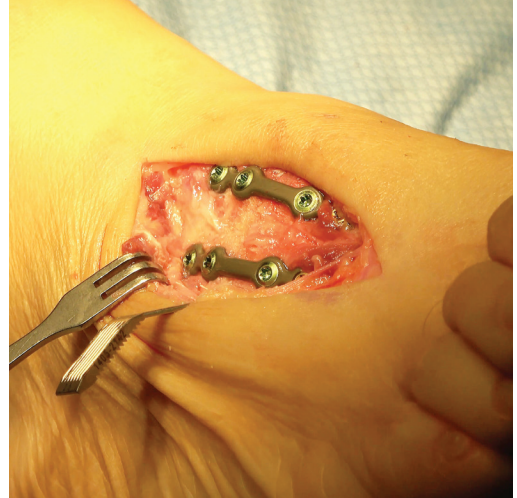

Lapiplasty® Plating

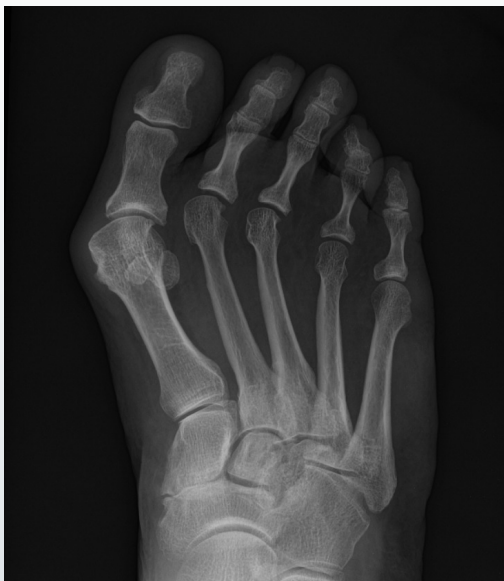Select a 4-hole **Lapiplasty® Lesser TMT Fixation Plate** and apply the plate to the dorsal surface of the 3rd TMT joint with the mid-section of the plate centered over the arthrodesis site. Confirm the plate position on fluoroscopy. Pre-drill and insert the appropriate locking screws.



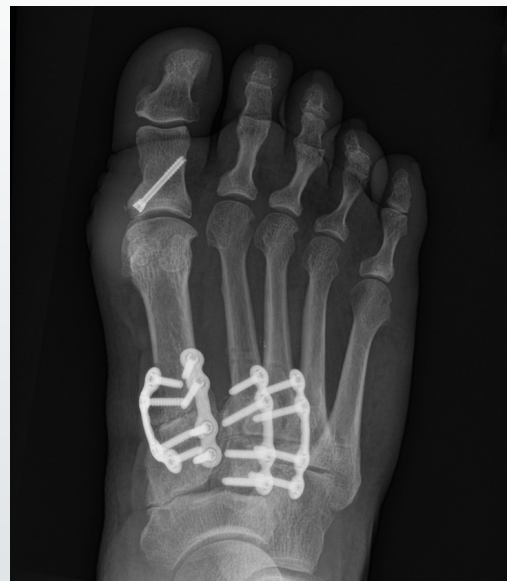Select an additional 4-hole **Lapiplasty® Lesser TMT Fixation Plate** and repeat the previous step for the 2nd TMT joint. Remove the **2.0mm Threaded Olive Wires** used for provisional fixation and confirm the final alignment with fluoroscopy.



Before



After



See surgical technique (LBL 1405-9001) and instructions for use (LBL 1405-9005) on www.treace.com for complete indications, contraindications, warnings, and precautions.

The Leader in Hallux Valgus Surgery™

TREACE
Medical Concepts, Inc.